

CASE REPORT

Lipoma of the oral mucosa: a case report

Sushruth Nayak*, Prachi Nayak

Department of and Oral Maxillofacial Pathology and Microbiology, Vyas Dental College and Hospital, Jodhpur, 342005, Rajasthan, India.

(Received 30 December 2010; accepted 6 June 2011)

Keywords

Lipoma,
oral mucosa,
palate,
tissue lesion.

Abstract Lipoma is a common tumor of soft tissue. Its location on the oral mucosa is rare, representing 1% to 5% of benign oral tumors although it is the most common mesenchymal tumor of the trunk and proximal portions of extremities. Lipoma of the oral cavity may occur in any region. The buccal mucosa, tongue, and floor of the mouth are among the common locations. The clinical presentation is typically as an asymptomatic yellowish mass. The overlying epithelium is intact, and superficial blood vessels are usually evident over the tumor. Other benign connective tissue lesions such as granular cell tumor, neurofibroma, traumatic fibroma and salivary gland lesions (mucocele and mixed tumor) might be included in differential diagnosis. We present a case of oral lipoma in an unusual location in the left palatal region opposite to premolars which is rare in the literature.

Introduction

Lipoma is defined as a benign, slow growing neoplasm composed of mature fat cells (Rajendran and Sivapathasundharam, 2007). Lipomas are common tumors in the human body (Del Castillo Pardo de Vera *et al.*, 2004; Chidzonga *et al.*, 2006) but are less frequent in the oral cavity, comprising no more than 1-5% of all neoplasms (Del Castillo Pardo de Vera *et al.*, 2004; Bandeca *et al.*, 2007; Trandafir *et al.*, 2007). They are commonly present as slow growing asymptomatic lesions with a characteristic yellowish color and soft, doughy feel in the buccal mucosa, floor of the mouth and tongue. They usually occur in the fourth and fifth decades of life with no sex predilection. Some studies, however, have shown a male predominance (Lawoyin *et al.*, 2001; Bandeca *et al.*, 2007; Adoga *et al.*, 2008). Half of oral lipomas are in the cheek and the remainders were found in the tongue, floor of the mouth, lips, palate and gingival mucosa (Vindenes, 1978). They are benign mesenchymal neoplasms composed of fat cells usually surrounded by a thin

fibrous capsule (Fregnani *et al.*, 2003). The size of tumor depends on the location but rarely exceeds 25 mm in diameter (Rapidis, 1982). Lipomas are usually asymptomatic until they grow to large size and may interfere with speech and mastication (Keskin *et al.*, 2002; Chidzonga *et al.*, 2006). Although malignant counterpart of this tumor, liposarcoma is another common soft tissue neoplasm, but its occurrence in oral cavity is rare (Favia *et al.*, 2001).

Case report

A sixty three year old male patient reported with the complaint of swelling and discomfort in the left palatal region opposite to premolars (24 and 25) since four months. The swelling was soft in consistency, non painful and measuring about 2.0x2.3cm in diameter (Fig. 1). The swelling was a soft pedunculated mass with a thin stalk attached to the base. Since there was no bony attachment at the base, the radiograph was not taken. Complete surgical excision was done. Macroscopically the resected mass was yellowish in colour and soft in consistency (Fig. 2). Histopathological examination disclosed the presence of keratinized stratified squamous epithelium with mature lipocytes and demonstrated a thin

* **Corresponding author:** Dr. Sushruth Nayak , Tel.: +919784579396, e-mail: drsushruthnayak@yahoo.co.in

fibrous capsule (Fig. 3). A distinct lobular arrangement of the cells was seen (Fig. 4). Patient was recalled after one week for suture

removal. The wound had healed uneventfully. Patient was followed up for six months without any signs of recurrence.

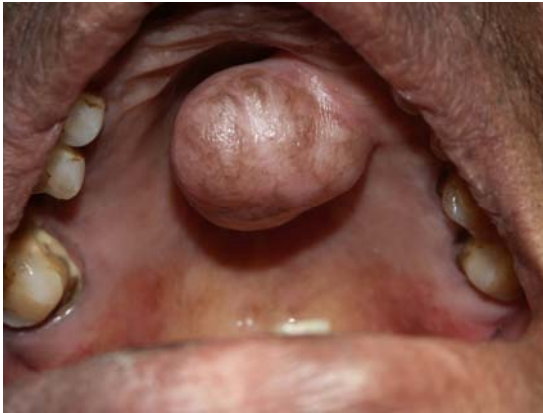

Figure 1 Intra oral view of the swelling.

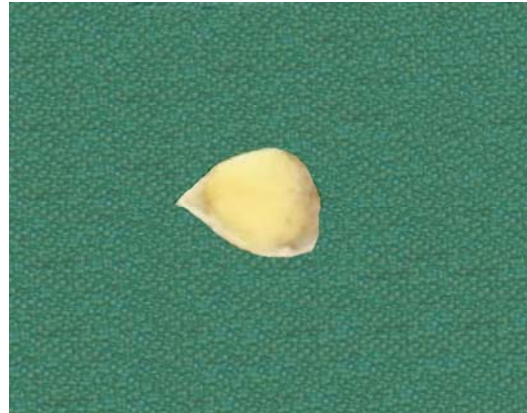

Figure 2 The resected specimen.

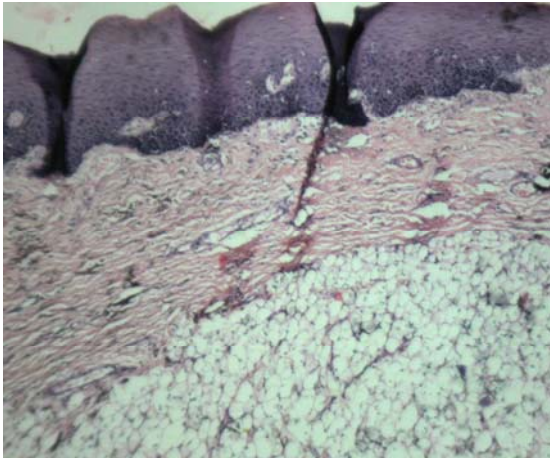


Figure 3 Section stained with Hematoxylin and Eosin showing keratinized epithelium and lipocytes (4 X).

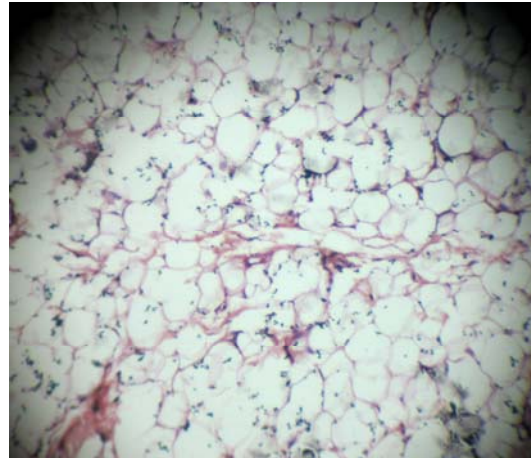


Figure 4 Section stained with Hematoxylin and Eosin showing lipocytes (10 X).

Discussion

To the best of our knowledge, only one case of lipoma in the hard palatal mucosa has been reported in the literature (Hoseini *et al.*, 2010). Lipomas are the most common mesenchymal tumors especially in trunk and proximal portions of the extremities but they are rare tumors of oral cavity (Del Castillo Pardo de Vera *et al.*, 2004; Chidzonga *et al.*, 2006; Bandeca *et al.*, 2007; Trandafir *et al.*, 2007). The present case was rare because of its occurrence in the palate. The lipomas present as slow growing asymptomatic lesions with yellowish color and soft, doughy feel, generally with no gender predilection. Other connective tissue lesions such as granular cell tumor, neurofibroma, traumatic fibroma, and

salivary gland lesions (mucocele and mixed tumor) might be included in the differential diagnosis (Lawoyin *et al.*, 2001; Bandeca *et al.*, 2007; Adoga *et al.*, 2008). Lipomas are well-defined in clinical examinations such as CT scan and MRI (Sakai *et al.*, 2006) which was similar to our case with respect to well defined margins. In some cases, they can be present as fluctuant nodules (Tan and Singh, 2004). Some other lesions should be considered in the differential diagnosis such as lymphoepithelial cysts, epidermoid and dermoid cysts (Anavi *et al.*, 1995). They may present as solitary or multiple lesions (Del Castillo Pardo de Vera *et al.*, 2004; Chidzonga *et al.*, 2006). Their mean size is 20 mm (Darling *et al.*, 2002) as compared to our case where it was 2x2.3cm. Microscopically, it is difficult to differentiate

between lipoma and normal adipose tissue. The microscopic appearance of a circumscribed but not encapsulated aggregate of mature adipocytes with large clear cytoplasm in the absence of vascularity is the diagnostic features of a classical lipoma (Adoga *et al.*, 2008). Our case showed the presence of mature lipocytes arranged in lobular pattern and demonstrated a thin fibrous capsule. Microscopically, the differential diagnoses are angioliipoma, liposarcoma and normal soft fatty tissue (Vindenes, 1978). Lipomas of oral cavity are rare, 50% of them are in buccal mucosa and less common sites are tongue, floor of the mouth and lips. Lipomas of palate are rare and most of them are developmental lesions. But true neoplasms of fat cells are rare in this place (Ebling and Wagner, 1967; Miles *et al.*, 1984). Surgical excision is the choice of treatment. Recurrence is reduced by wide surgical excision (Del Castillo Pardo de Vera *et al.*, 2004) as followed in this case report. Infiltrating lipomas are difficult to extirpate and are liable for recurrence (Chidzonga *et al.*, 2006; Adoga *et al.*, 2008).

References

- Adoga AA, Nimkur TL, Manasseh AN, Echejoh GO (2008). Buccal soft tissue lipoma in an adult Nigerian: a case report and literature review. *J Med Case Reports*, **2**: 382.
- Anavi Y, Gross M, Calderon S (1995). Disturbed lower denture stability due to lipoma in the floor of the mouth. *J Oral Rehabil*, **22**(1): 83-85.
- Bandeca MC, de Padua JM, Nadalin MR, Ozorio JE, Silva-Sousa YT, Cruz Perez DE (2007). Oral soft tissue lipomas: a case series. *J Can Dent Assoc*, **73**(5): 431-434.
- Chidzonga MM, Mahomva L, Marimo C (2006). Gigantic tongue lipoma: a case report. *Med Oral Pathol Oral Cir Bucal*, **11**(5): 437-439.
- Darling M, Thompson I, Schneider J (2002). Spindle cell lipoma of the alveolar mucosa: a case report. *Oral Surg Oral Med Oral Pathol Oral Radiol Endod*, **93**(2): 171-173.
- Del Castillo Pardo de Vera JL, Cebrian Carretero JL, Gomez GE (2004). Chronic lingual ulceration caused by lipoma of the oral cavity: Case report. *Med Oral*, **9**(2): 166.
- Ebling H, Wagner JE (1967). Lipoma of the soft palate. *Rev Fac Odontol P Alegre*, **9**:163-168.
- Favia G, Maiorano E, Orsini G, Piattelli A (2001). Myxoid liposarcoma of the oral cavity with involvement of the periodontal tissues. *J Clin Periodontol*, **28**(2): 109-112.
- Fregnani ER, Pires FR, Falzoni R, Lopes MA, Vargas PA (2003). Lipomas of the oral cavity: clinical findings, histological classification and proliferative activity of 46 cases. *Int J Oral Maxillofac Surg*, **32**(1): 49-53.
- Hoseini AT, Razavi SM, Khabazian A (2010). Lipoma in Oral Mucosa: Two case reports. *Dent Res J*, **7**(1): 41-43.
- Keskin G, Ustundag E, Ercin C (2002). Multiple infiltrating lipomas of the tongue. *J Laryngol Otol*, **116**(5): 395-397.
- Lawoyin JO, Akande OO, Kolude B, Agbaje JO (2001). Lipoma of the oral cavity: clinicopathological review of seven cases from Ibadan. *Niger J Med*, **10**(4): 189-191.
- Miles DA, Langlais RP, Aufdemorte TB, Glass BJ (1984). Lipoma of the soft palate. *Oral Surg Oral Med Oral Pathol*, **57**(1): 77-80.
- Rajendran R, Sivapathasundharam B (2007). *Shafer's Textbook of Oral Pathology*, 5th edn. New Delhi: Elsevier Health Sciences, pp. 194.
- Rapidis AD (1982). Lipoma of the oral cavity. *Int J Oral Surg*, **11**(1): 30-35.
- Sakai T, Iida S, Kishino M, Okura M, Kogo M (2006). Sialolipoma of the hard palate. *J Oral Pathol Med*, **35**(6): 376-378.
- Tan MS, Singh B (2004). Difficulties in diagnosing lesions in the floor of the mouth-report of two rare cases. *Ann Acad Med Singapore*, **33**(4): 72-76.
- Trandafir D, Gogalniceanu D, Trandafir V, Caruntu ID (2007). Lipomas of the oral cavity-a retrospective study. *Rev Med Chir Soc Med Nat Iasi*, **111**(3): 754-758.
- Vindenes H (1978). Lipomas of the oral cavity. *Int J Oral Surg*, **7**(3): 162-166.