

Case Report

Haemodialysis associated amyloidosis of the tongue: a case report

Hans Prakash Sathasivam^{a*}, Lau Shin Hin^b,

^a Oral Medicine and Oral Pathology Unit, Hospital Sultan Ismail, Jalan Persiaran Mutiara Emas Utama, Taman Mount Austin, 81100 Johor Bahru, Johor Malaysia.

^b Institute for Medical Research, Jalan Pahang, 50588 Kuala Lumpur, Malaysia.

* Corresponding author: hansprakash@hotmail.com

Revised edition: 19/10/2013. Accepted: 31/12/2013. Published online: 31/12/2013.

Abstract Haemodialysis associated amyloidosis (HAA) is a complication of long-term haemodialysis caused by deposition of β_2 -microglobulin in tissues that most often presents clinically at osteoarticular sites. However, in very rare circumstances, patients do present initially with oral manifestations of HAA. In a normally functioning kidney, β_2 -microglobulin is cleared by glomerular filtration and is catabolized in the proximal tubules. This article describes a patient with oral manifestation of haemodialysis associated amyloidosis with an unusual presenting complaint of lingual dysaesthesia.

Keywords: Amyloidosis, beta-2 microglobulin, hemodialysis, oral, tongue.

Introduction

Haemodialysis associated amyloidosis (HAA) is a known complication in long-term haemodialysis patients that has been recognized as being caused by deposition of β_2 -microglobulin amyloid in various tissues (Fuchs *et al.*, 1987; Guccion *et al.*, 1989; Ohashi, 2001). β_2 -microglobulin is actually a normal serum protein that is part of the Major Histocompatibility Complex (MHC) Class I molecule. Most conventional renal dialysis membranes do not allow passage of β_2 -macroglobulin into the kidney, leading to high serum concentrations of this protein ensuing in its deposition at various sites in the body.

β_2 -microglobulin amyloid has been found to usually deposit in the osteo-articular system especially involving large bones close to the joint spaces, and synovial membranes (Bardin *et al.*, 1987; Ullian *et al.*, 1989; Ohashi, 2001). Although involvement of extra-articular locations have been documented, they are rare (Al-Hashimi *et al.*, 1987; Noël *et al.*, 1987; Gal *et al.*, 1994; Matsuo *et al.*, 1997; Stoopler *et al.*, 2003). Aside from being infrequent, extra-articular deposition of this protein is thought to occur late in the course of the disease (Noël *et al.*, 1987).

With the progressive numerical increase of long-term haemodialysis patients, the occurrence of HAA in soft tissues is expected to increase. However, HAA involving the oral tissues is an exceedingly rare phenomenon and is almost always preceded by osteo-articular involvement (Noël *et al.*, 1987; Gal *et al.*, 1994; Matsuo *et al.*, 1997; Stoopler *et al.*, 2003). An important predictive factor for the development of HAA is the duration of haemodialysis, with the risk being higher in patients who have been on haemodialysis for more than 10 years (Jimenez *et al.*, 1998). Currently, there is no specific treatment for HAA and even reduction of circulating serum β_2 -microglobulin levels do not cause regression of bony lesions. Here, we present a patient whose initial presentation of HAA was within the oral cavity.

Case history

Informed consent was obtained from the patient involved for all clinical procedures as well as for participation in this report. A 57-year-old female patient was referred to the Oral Medicine Clinic for assessment and management of lingual dysaesthesia. The patient described having an unpleasant

sensation of the tongue that has been present for a couple of years. She had been seen by a number of dental and medical specialists for this problem without obtaining a definitive answer to her woes.

The patient has been on haemodialysis due to renal failure for more than 15 years and she also has a history of hypertension, atrial fibrillation as well as a positive history of hepatitis B and C. She has no history of smoking, alcohol ingestion or drug abuse.

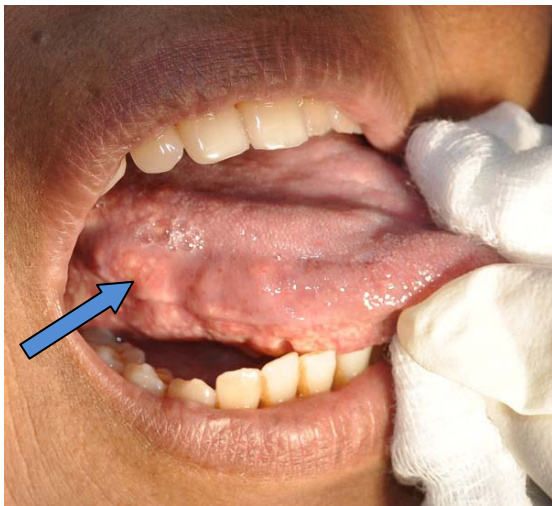


Fig. 1 Multiple nodules of whitish-yellow colour (blue arrow) were detected on the latero-ventral surfaces of the patient's tongue.

Upon clinical examination, multiple nodules of whitish-yellow colour were detected on the dorsum and latero-ventral surfaces of the patient's tongue (Fig. 1). These nodules were firm, fixed and unpleasant upon palpation. The patient affirmed that the lingual dysaesthesia was predominantly in the areas with these nodules and that these nodules were increasing in number and size. Due to the presence of these nodules that were suggestive of amyloid deposits and the negative findings for other possible local causes of the dysaesthesia such as damage or trauma to the lingual nerve; either from dental procedures or craniofacial trauma, a biopsy of the lingual nodules was carried out under local anaesthesia to determine the underlying pathology. The specimen was then sent for a histopathological examination.

Whilst awaiting the histopathological report, the patient underwent extensive

workup to determine the presence of previously undetected systemic conditions. The patient was screened for nutritional deficiencies (vitamins B1, B6, B12 and E), blood dyscrasias (full blood count with differentiation), diabetes mellitus (glucose tolerance test and HbA1c), connective tissue disease (anti-nuclear antibodies and rheumatoid factor) and for HIV, as all these conditions may cause peripheral neuropathy. The tests failed to yield any additional information as they were all negative or within the normal reference ranges. The patient also underwent neurological assessment to rule out possible central lesions that may affect the sensory nerve supply to the tongue. The neurological assessment showed no obvious abnormality except for the localized lingual dysaesthesia.

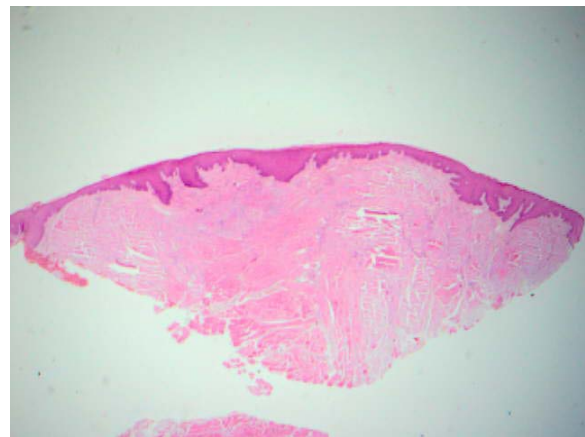


Fig. 2 Amorphous eosinophilic subepithelial deposits (Haematoxylin & Eosin stain; at 20 x magnification).

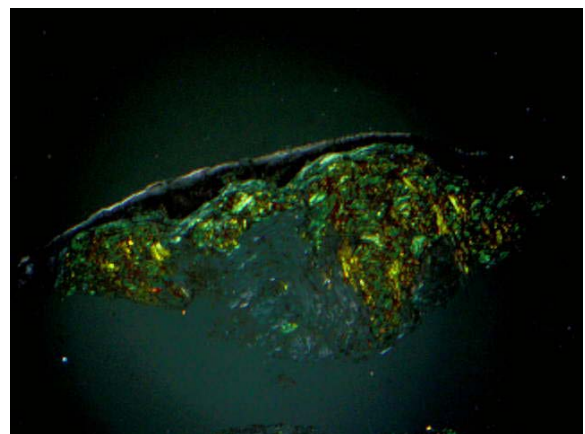


Fig. 3 Deposits displaying an apple-green birefringence under polarized light (Congo red technique; at 20 x magnification)

The biopsy sample was formalin-fixed and paraffin embedded. Subsequently, sections were taken for haematoxylin and eosin (H&E) staining, and for special stains to detect amyloid deposits. Congo red was chosen as the special stain to detect amyloid due to its ease of use as well as high specificity and sensitivity to amyloid deposits. Using light microscopy, H&E staining revealed amorphous, homogeneous eosinophilic deposits located in the sub-epithelial region (Fig. 2). The deposits stained positively with Congo red staining and when viewed under polarized light, these deposits displayed an apple-green birefringence (Fig. 3).

Due to the history of long-term haemodialysis and renal failure, the case was discussed with the patient's physician and determination of serum β 2-microglobulin level was performed. Serum level of β 2-microglobulin in the patient was also elevated far above the reference range specified for her age and gender. With these findings, the deposits were diagnosed as haemodialysis associated amyloid deposits.

Management of lingual HAA is very much dependent on the extent of local involvement as well as presence/absence of systemic involvement. For this patient, further investigations were conducted to determine extra-oral involvement whilst the lingual deposits were managed conservatively. Following the biopsy, the patient noticed an improvement in the extent of the lingual dysaesthesia. However, as there were still some sub-epithelial nodules left, she was given the option for complete surgical removal of the remaining lingual amyloid nodules, which she declined. After further discussion with the patient's attending physician, it was decided that the physicians will proceed with further management including clinical and radiological examination to determine whether there were other sites involved with emphasis on osteo-articular sites.

Discussion

The increased amount of β 2-microglobulin in the patient's serum is thought to be due to two inter-related reasons; decreased renal function and the characteristics of dialysis membranes that disallow elimination of β 2-microglobulin. As such, patients who have

undergone haemodialysis for longer periods of time have a higher risk of developing HAA (Jimenez *et al.*, 1998). The patient presented here has had haemodialysis for more than 15 years due to renal failure and as such, it was not surprising that she developed HAA.

It was however, unusual that her presenting complaint of lingual dysaesthesia was due to HAA. Oral/visceral symptoms of HAA are almost always chronologically preceded by symptoms from the osteo-articular system. HAA involving osteo-articular sites have been known to cause carpal tunnel syndrome, osteoarthropathy and bone cysts (Bardin *et al.*, 1987; Ohashi, 2001).

Diagnosis of HAA is highly dependent on clinical as well as histopathological findings (Al-Hashimi *et al.*, 1987; Matsuo *et al.*, 1997; Stoopler *et al.*, 2003; Fahrner *et al.*, 2004). Reaching a diagnosis in this case was further complicated by the fact that her main complaint was that of abnormal sensation of the tongue, and as such, a thorough clinical, serological and radiological investigation had to be performed to rule out any other possible causes of lingual dysaesthesia. The International Association for the Study of Pain (IASP) has defined dysaesthesia as "an unpleasant abnormal sensation, whether spontaneous or evoked" (IASP, 2012). The dysaesthesia in this patient was most likely caused by compression of the nerve bundles by the progressively enlarging amyloid deposits.

Despite the rather pathognomonic appearance of the amyloid deposits, a biopsy is mandatory to rule out other pathological processes that may have similar clinical presentations. Other more common lingual manifestations of HAA besides dysaesthesia include; macroglossia, restricted mobility and difficulty in articulation (Guccion *et al.*, 1989; Matsuo *et al.*, 1997).

In summary, HAA of the tongue, although a rare complication of long term haemodialysis and renal failure, may at times be the only indicator of HAA. Early recognition and adequate investigation can ensure better medical care for these patients.

Acknowledgement

The authors would like to thank the Director of Health Malaysia for his permission to publish this paper.

References

- Al-Hashimi I, Drinnan AJ, Uthman AA, Wright JR, Levine MJ (1987). Oral amyloidosis: two unusual case presentations. *Oral Surg Oral Med Oral Pathol*, **63**(5): 586-591.
- Bardin T, Zingraff J, Shirahama T *et al.* (1987). Hemodialysis-associated amyloidosis and beta-2 microglobulin. Clinical and immunohistochemical study. *Am J Med*, **83**(3): 419-424.
- Fahrner KS, Black CC, Gosselin BJ (2004). Localized amyloidosis of the tongue: a review. *Am J Otolaryngol*, **25**(3): 186-189.
- Fuchs A, Jagirdar J, Schwartz IS (1987). Beta 2-microglobulin amyloidosis (AB2M) in patients undergoing long-term hemodialysis. A new type of amyloid. *Am J Clin Pathol*, **88**(3): 302-307.
- Gal R, Korzets A, Schwartz A, Rath-Wolfson L, Gafer U (1994). Systemic distribution of beta 2-microglobulin-derived amyloidosis in patients who undergo long-term hemodialysis. Report of seven cases and review of the literature. *Arch Pathol Lab Med*, **118**(7): 718-721.
- Guccion JG, Redman RS, Winne CE (1989). Hemodialysis-associated amyloidosis presenting as lingual nodules. *Oral Surg Oral Med Oral Pathol*, **68**(5): 618-623.
- International Association for the Study of Pain (IASP) (2012). IASP Taxonomy. [online] Available at: <<http://www.iasp-pain.org/Content/NavigationMenu/GeneralResourceLinks/PainDefinitions/default.htm>> [Accessed 1 August 2013].
- Jimenez RE, Price DA, Pinkus GS *et al.* (1998). Development of gastrointestinal beta2-microglobulin amyloidosis correlates with time on dialysis. *Am J Surg Pathol*, **22**(6): 729-735.
- Matsuo K, Nakamoto M, Yasunaga C, Goya T, Sugimachi K (1997). Dialysis-related amyloidosis of the tongue in long-term hemodialysis patients. *Kidney Int*, **52**(3): 832-838.
- Noël LH, Zingraff J, Bardin T, Atienza C, Kuntz D, Drüeke T (1987). Tissue distribution of dialysis amyloidosis. *Clin Nephrol*, **27**(4): 175-178.
- Ohashi K (2001). Pathogenesis of beta2-microglobulin amyloidosis. *Pathol Int*, **51**(1): 1-10.
- Stoopler ET, Sollecito TP, Chen SY (2003). Amyloid deposition in the oral cavity: A retrospective study and review of the literature. *Oral Surg Oral Med Oral Pathol Oral Radiol Endod*, **95**(6): 674-680.
- Ullian ME, Hammond WS, Alfrey AC, Schultz A, Molitoris BA (1989). Beta-2-microglobulin-associated amyloidosis in chronic hemodialysis patients with carpal tunnel syndrome. *Medicine (Baltimore)*, **68**(2): 107-115.