

Case Report

Sublingual epidermoid cyst resembling sublingual ranula: a case report

Tan Shi Nee ^a, Roszalina Ramli ^b, Primuharsa Putra Sabir Husin Athar ^{c*}

^a Dept. of Otorhinolarygology-Head & Neck Surgery, School of Medicine, KPJ Healthcare University College, Malaysia.

^b Department of Oral & Maxillofacial Surgery, Universiti Kebangsaan Malaysia.

^c Ear, Nose & Throat-Head & Neck Consultant Clinic, KPJ Seremban Specialist Hospital/ KPJ Healthcare University College, Negeri Sembilan, Malaysia.

* Corresponding author: putrani@yahoo.co.uk

Submitted: 18/11/2014. Revised edition: 23/02/2015. Accepted: 12/05/2015. Published online: 13/05/2015.

Abstract Dermoid cysts are anatomic embryonic abnormalities that are rarely seen in the oral cavity. Histologically, they are further classified as epidermoid, dermoid or teratoid. We report a case in which an 18-year-old girl who developed an epidermoid cyst presenting as a large sublingual swelling occupying the entire floor of the mouth causing snoring and speech difficulty. We emphasized on the clinical steps in achieving an accurate diagnosis, possible differential diagnosis, necessary imaging techniques and management of epidermoid cyst.

Keywords: enucleation, epidermoid cyst, ranula, sublingual.

Introduction

Dermoid cyst is a benign cystic malformation that is rarely seen in the oral cavity (Jham *et al.*, 2007). It represents less than 0.01% of all oral cavity cysts (Verma *et al.*, 2012; De Ponte *et al.*, 2002; Patil *et al.*, 2009). Histologically, the cysts can be divided into epidermoid (lining of epithelium only), dermoid (lining with skin adnexa within the wall) and teratoid (when other tissues such as muscle, bone or cartilage are present) (Verma *et al.*, 2012; De Ponte *et al.*, 2002; Patil *et al.*, 2009; Khairul *et al.*, 2007). Epidermoid cysts are said to be the most common type and teratoid cysts are the least common in the sublingual region in the oral cavity (Yilmaz *et al.*, 2006). Although there are no clear data which showed the incidence of the various forms in the oral cavity, floor of the mouth in the midline is the most common site (Patil *et al.*, 2009). However, there are occasional occurrence seen involving the tongue, lips and buccal mucosa (Shear and Speight, 2007).

Dermoid cyst can be classified as congenital or acquired. A lot of etiopathogenesis theories have been reported which includes dysontogenetic, traumatic, and thyroglossal anomaly (Jham *et al.*, 2007; Verma *et al.*, 2012). Many researchers believed that congenital cysts are dysembryogenetic lesions which resulted from ectodermal elements which were entrapped during the midline fusion of the first and second branchial arches during fetal development (Jham *et al.*, 2007; Verma *et al.*, 2012; Patil *et al.*, 2009). Acquired cysts are derived from traumatic or iatrogenic inclusion epidermal cells or from occlusion of sebaceous gland duct (Khairul *et al.*, 2007). Recently, it was proposed that midline cysts may represent a variant form of thyroglossal duct cyst (Verma *et al.*, 2012; Khairul *et al.*, 2007; Kandogan *et al.*, 2007).

In this report, we describe a young girl who presented with a cystic sublingual lesion occupying the entire floor of the mouth.

Case report

An 18-year-old girl with an unremarkable past medical history presented with a history of painless huge swelling which is slow growing at the floor of the mouth for 18 months. It was gradually increasing in size. She reported mild discomfort in swallowing and speaking but well tolerated. Otherwise, there was no dysphagia or odynophagia. No periodic swelling during eating. There was no history of fever and mastication problem.

Intraoral examination revealed a 4 x 3 cm, cystic sublingual swelling occupying the floor of the mouth (Fig. 1), which crosses the midline anteriorly. Right lateral tongue was elevated by the swelling. The swelling is smooth-surfaced, non-ulcerated and normal coloured with well-defined margins. It is rubbery, fluctuant, soft in consistency and non-tender on palpation. On bimanual palpation of the duct, there was no discharge seen. No other additional mucosal lesions were seen. No palpable swelling in the neck.

Computed tomography (CT) of the neck revealed cystic swelling at the right sublingual region on the floor of the mouth above the mylohyoid muscle (Fig. 2). It was hypodense in appearance and crosses the midline. This lesion is homogenous and has

an imperceptible wall and no significant enhancement post-contrast. It measures as 3 x 5 cm in axial diameter. No associated solid component or calcific foci. The adjacent right submandibular gland appears normal in size; however, there is a slight dilatation of the right submandibular duct. No obvious intraductal calculus was seen. No bony erosion and enlarged lymph nodes or invasion of adjacent structures were observed.

She underwent intraoral excision of the mass under general anaesthesia. Local infiltration of marcaine with adrenaline of about 5 cc was given around the site of incision followed by mucosal incision. Intraoperatively, the capsule of the cyst is thick. Lingual nerve and submandibular duct were identified and preserved. Sublingual gland was also preserved. Mucosa was closed with vicryl suture.

Post-operative recovery was uneventful. Histopathology examination reported as epidermal cyst (Fig. 3). On the initial follow-up, 2 weeks post operation, she has no more complaint of discomfort in swallowing as well as in speech articulation. The patient was followed-up for 3 year with no signs of recurrence.

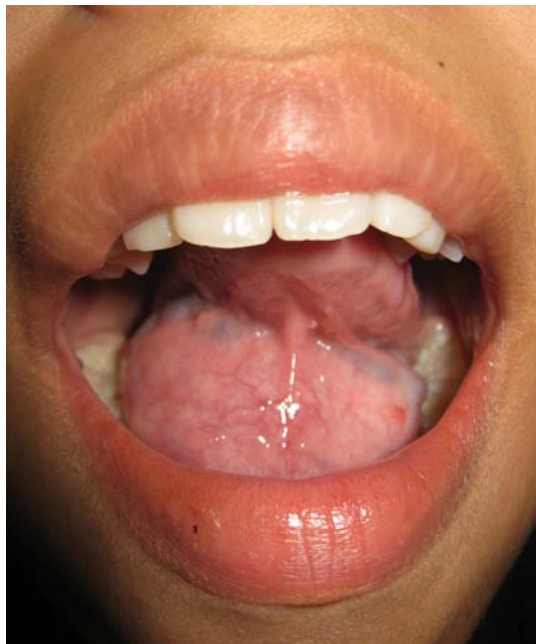

Fig. 1 Photograph showed swelling at the floor of the mouth. The wall appearance is not translucent.

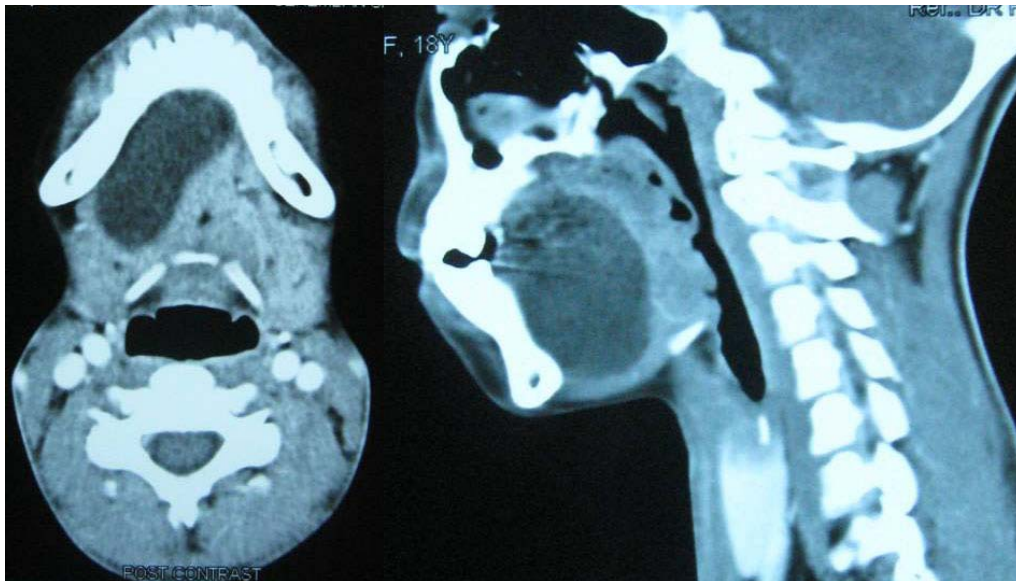

Fig. 2 CT scan showed hypodense swelling at the floor of the mouth measured 2 x 1 cm.

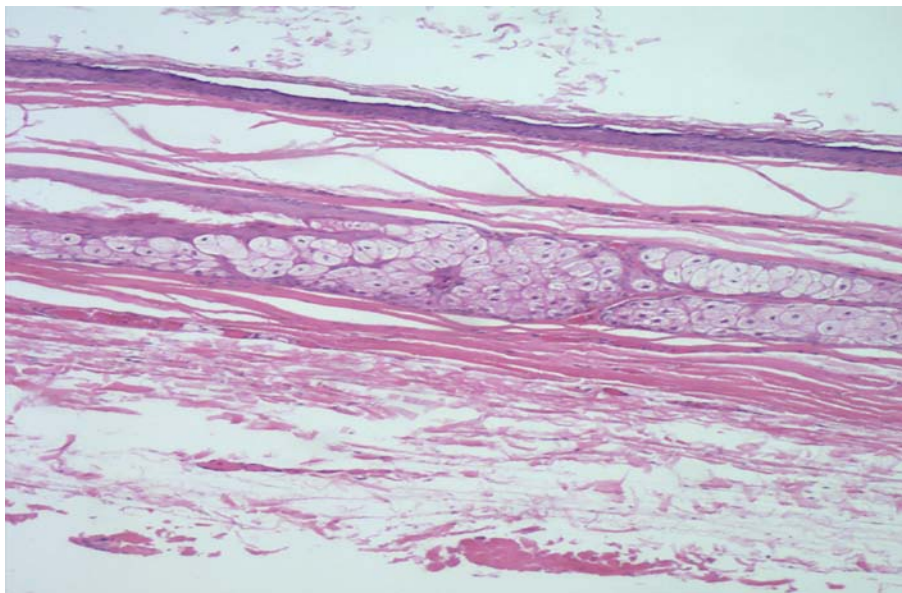


Fig. 3 Histology showed excised cyst with fairly thin fibrous wall lined by stratified squamous epithelium displaying keratinization with a few keratin materials is seen in the lumen. Fibrous stroma is markedly collagenized.

Table 1 Differential diagnosis of swellings of the floor of the mouth or neck (Jham *et al.*, 2007)

Category	Lesion	Signs and symptoms
Tumours	Benign (mesenchymal, salivary gland) tumours	Displacement of adjacent structures, slow-growing, smooth surface
	Malignant tumours	Ulcerated surface, invasion of adjacent structures, metastatic lymph nodes
Mucous extravasation phenomena	Ranula	Bluish-translucent coloration, soft, fluctuant
Embryonic abnormalities	Dermoid cyst (epidermoid, dermoid and teratoid cyst)	Swelling in midline floor of the mouth or neck; slow-growing, painless
	Cervical lymphoepithelial cyst	Upper lateral neck swelling without an intraoral component
	Thyroglossal duct cyst	Classically in the midline of the neck; first 2 decades of life
Infections	Intraoral source of infection (periapical abscess, pericoronitis, sialadenitis)	Rapid progression, pain, fever; warm overlying skin; obvious intraoral source

Discussion

There were several synonyms which exist for epidermoid cysts, including epidermal cyst, epidermal inclusion cyst, and keratin cyst (Yilmaz *et al.*, 2006). There are no difference in presentation and histology of epidermoid cyst either if they are congenital or acquired type.

Epidermoid cysts are generally diagnosed in young adults in the second and third decades of life (Khairul *et al.*, 2007; Kandogan *et al.*, 2007; Longo *et al.*, 2003) documented that in a series of 16 cases, it was found that men are affected more than women in a ratio of 3:1, with mean age of 27.8 years. Other previous papers have found that no gender predilection exists (Longo *et al.*, 2003). Patient usually presents with a swelling in the floor of the mouth which is generally slow and progressive growth. They are usually asymptomatic painless mass that is usually located in the midline, above or below the mylohyoid muscle (James *et al.*, 2011).

In the present report, the sublingual swelling was above the mylohyoid muscle which was reported as the most common

location (Tsirevelou *et al.*, 2009). Our patient has speech and swallowing difficulties which are the common symptoms (Jham *et al.*, 2007). Other potential problems which were not seen in our patient are airway obstruction, mastication, dysphagia, dyspnea because they can displace the tongue due to the upward and medial displacement of the tongue, but it is rare. In the case of lower localization, they may present a characteristic of double chin (Longo *et al.*, 2003).

When sublingual swelling is suspected, there are a few things to be considered as differential diagnosis, which includes tumours, mucous extravasation phenomena, anatomic abnormalities arising during embryonic development and infections (Verma *et al.*, 2012; Khairul *et al.*, 2007; Longo *et al.*, 2003; James *et al.*, 2011). Ranula, known as mucous extravasation of the sublingual salivary gland; should be one of the differential diagnosis in patient presenting with swelling in the floor of mouth.

Ranulas are ranked 41st common oral lesions with a prevalence of 0.2 cases per

1000 people (Bahnassy, 2009), in contrast to epidermoid cyst which is rare in the oral cavity (1.6–1.8%) mostly occurring in the sublingual region (Abdulai *et al.*, 2014)

Table 1 (Jham *et al.*, 2007) summarizes the clinical features important in the differential diagnosis of sublingual or cervical swellings. In the present case, based from the Table 1, there are two main diagnostic possibilities, which are: a mucous extravasation phenomenon and embryonic abnormalities. Due to the symptoms was compatible with ranula, thus, that was our first initial hypothesis. Another provisional diagnosis was thought to be a dermoid cyst, lipoma or sialadenosis. Other differential diagnoses such as infection was discarded due to the absence of pain and intraoral infection. Tumour was ruled out in view of the lesion's clinical signs and absence of lymphadenopathy. Table 1 was highlighted, as it tabulates a list of possible lesions and corresponding structures arising from the floor of the mouth. Common diagnosis of a ranula for floor of mouth swelling can be misleading as shown in the present case report. Thus, it is important to consider other possible differential diagnosis and correlate it clinically.

Imaging techniques can be used for pre-operative diagnosis and surgical planning where differential diagnosis of sublingual swellings is more challenging. Ultrasonography can be one of the first choices of imaging used because it can establish the nature of the lesion besides being economical, cost-effective and without X-ray exposure. By knowing the nature of the lesion, it can give the rough idea to the surgeon for the correlation of the possible diagnosis (Jain *et al.*, 2010). However, magnetic resonance imaging (MRI) and computed tomography (CT) allow more precise localization of the lesion, and also enable the surgeon to choose the most appropriate approach (Kandogan *et al.*, 2007), thus they are more superior than ultrasonography. Some authors prefer MRI over CT as a diagnostic tool for dermoid cysts (Jham *et al.*, 2007; Khairul *et al.*, 2007), as it is superior in terms of soft-tissue resolution and, thus, better able to depict the internal structure of a mass

lesion. However, it should be emphasized that, imaging techniques are not able to determine the specific histologic subtypes (Jham *et al.*, 2007).

We proceeded with CT scan in the present case, which showed the presence of hypodense swelling in the floor of the mouth measured 2 x 1 cm. We did not carry out any further investigations as CT scan offered such clarity and we were able to delineate the anatomy and assist in the surgical pre-operative assessment.

Later on, during intraoperative, the lesion excised showed a smooth lining containing sebum-like material with a few keratin material seen in the lumen. This made a diagnosis of a dermoid cyst, a possible choice.

In the present case, the histopathology report showed section of excised cyst with fairly thin fibrous wall lined by stratified squamous epithelium displaying keratinisation, characterizing it as an epidermoid cyst.

All the other possibilities of sublingual lesions can be ruled out on the basis of CT scan and histopathology (Jham *et al.*, 2007; Patil *et al.*, 2009).

The treatment of dermoid cysts of the floor of mouth is surgical. Several techniques are proposed in which can be divided into intraoral or extraoral approach depending on which approach is used as according to the localization and size of the mass to relieve symptoms caused by the cyst or possible infection (Jham *et al.*, 2007; Patil *et al.*, 2009; Kandogan *et al.*, 2007; Longo *et al.*, 2003).

We used the intraoral approach in the present case, as the CT scan findings showed the cyst is above the mylohyoid muscle thus cyst was easily accessible through this route. This approach is more feasible compared to extraoral approach. The cyst was easily excised with good post-operative recovery. This approach is supported by Akao *et al.* (2003) who state that intraoral access must be attempted first, even if dealing with a large cyst. Intraoral approach gives good cosmetic and functional results (Yilmaz *et al.*, 2006; Tsirevelou *et al.*, 2009).

Post-operative complications are rare and are reduced by closely following the

capsule and its complete removal (Patil *et al.*, 2009; Kandogan *et al.*, 2007). However, the possible complications in which the surgery of the floor of mouth may damage structures in sublingual space, leading to potential life-threatening complications such as hemorrhage from the lingual vessels and hematoma formation which can lead to significant swelling and edema of the floor of mouth and tongue, resulting in respiratory distress and airway obstruction from elevation of the tongue against the palatal vault. Overall, the prognosis is good as malignant transformation of a dermoid cyst and its chances of recurrence are rare. (Jham *et al.*, 2007; Patil *et al.*, 2009; Khairul *et al.*, 2007; Kandogan *et al.*, 2007).

Conclusion

We describe a case of epidermoid cyst in the sublingual region presenting as intraoral swelling was successfully diagnosed and managed by following simple effective steps. The cyst was completely excised through intraoral incision without any complications and without any evidence of recurrence in 3 years follow-up.

References

- Akao I, Nobukiyo S, Kobayashi T, Kikuchi H, Koizuka I (2003). A case of large dermoid cyst in the floor of the mouth. *Auris Nasus Larynx*, 30(Suppl): S137-S139.
- Abdulai AE, Avogo D, Nuamah IK, Baddoo H, Gyasi RK (2014). Large lateral dermoid cyst mimicking plunging ranula: a case report and intraoral approach to surgical management. *Int J Case Rep Images*, 5(6): 408-412.
- Bahnassy M (2009). A huge oral ranula. *Oman Med J*, 24(4): 306-307.
- De Ponte FS, Brunelli A, Marchetti E, Bottini DJ (2002). Sublingual epidermoid cyst. *J Craniofac Surg*, 13(2): 308-310.
- Jain P, Jain R, Morton RP, Ahmad Z (2010). Plunging ranulas: high-resolution ultrasound for diagnosis and surgical management. *Eur Radiol*, 20(6): 1442-1449.
- James WD, Elston DM, Berger TG, Andrews GC (2011). *Andrew's Diseases of the Skin: Clinical Dermatology*. London: Saunders/Elsevier.
- Jham BC, Duraes GV, Jham AC, Santos CR (2007). Epidermoid cyst of the floor of the mouth: a case report. *J Can Dent Assoc*, 73(6): 525-528.
- Kandogan T, Koç M, Vardar E, Selek E, Sezgin O (2007). Sublingual epidermoid cyst: a case report. *J Med Case Rep*, 1: 87.
- Khairul S, Primuharsa Putra SHA, Ramli R (2007). Sublingual epidermoid cyst mimicking plunging ranula. *Mal J Oral Maxillofac Surg*, 5: 28-30.
- Longo F, Maremonti P, Mangone GM, De Maria G, Califano L (2003). Midline (dermoid) cysts of the floor of the mouth: report of 16 cases and review of surgical techniques. *Plast Reconstr Surg*, 112(6): 1560-1565.
- Patil K, Mahima VG, Malleshi SN (2009). Sublingual epidermoid cyst: a case report. *Cases J*, 2: 8848.
- Shear M, Speight P (2007). *Cysts of the Oral and Maxillofacial Regions*. 4th edn. Oxford: Blackwell Munksgaard, pp. 181-183.
- Tsirevelou P, Papamanthos M, Chlopsidis P, Zourou I, Skoulakis C (2009). Epidermoid cyst of the floor of the mouth: two case reports. *Cases J*, 2: 9360.
- Verma S, Kushwaha JK, Sonkar AA, Kumar R, Gupta R (2012). Giant sublingual epidermoid cyst resembling plunging ranula. *Natl J Maxillofac Surg*, 3(2): 211-213.
- Yilmaz I, Yilmazer C, Yavuz H, Bal N, Ozluoglu LN (2006). Giant sublingual epidermoid cyst: a report of two cases. *J Laryngol Otol*, 120(3): E19.